

LETTER TO THE EDITOR

Genital lichen sclerosis in women: a histopathological analysis of 38 criteria

Editor

Lichen sclerosis (LS) is a chronic, progressive and invalidating inflammatory dermatosis affecting mainly the anogenital skin.¹ Particularly in early stages, it is difficult to distinguish LS from other dermatoses, because both the clinical and histopathological pictures may be equivocal.²⁻⁴ Only in few studies published to date, several different histological features of LS were discussed in the same population.^{2,5-8}

We performed a cross-sectional analysis of 38 histopathological features in vulvar biopsies from previously untreated premenopausal female patients with a clinical suspect of LS. The dermatoses were further confirmed as LS when histologically at least a subepidermal sclerosis and/or a lichenoid inflammation were present, and after ruling out other evident diagnoses.

Among 68 screened patients (mean age: 32.2 ± 8.3 years), 29 met the LS criteria. In 39 patients, the biopsy showed a spongiotic dermatitis ($n = 18$), lichen simplex chronicus (LSC) ($n = 12$), unspecific dermatosis ($n = 8$) and one fungal infection. LS was significantly associated with the following 10 features (decreasing importance, Fig. 1): lichenoid inflammation, subepidermal sclerosis, band-like inflammation, loss of rete ridges, erythrocytes extravasation, moderate-to-strong dermal inflammation, loss of elastic fibres within sclerosis/fibrosis, presence of apoptotic keratinocytes, dermal fibrosis and absence of epidermal acanthosis. The presence of both subepidermal sclerosis and lichenoid inflammation was observed in only seven (24%) LS cases. In absence of a lichenoid inflammation and/or of a subepidermal sclerosis, an affirmative histological diagnosis of LS is very difficult.^{5,6} Hence, the knowledge of other important histological criteria may be helpful.

A lichenoid inflammation was observed in LS in up to 80% of our cases, and in half of them, the infiltrate was band-like, but without further characteristics indicating lichen planus (LP).⁷ A band-like inflammation was significantly more frequent (40%) in the LS than in non-LS cases (40% vs. 5.1%).

Most authors describe a subepidermal sclerosis as a hallmark of LS,⁹ or as the crucial differentiating feature whenever other histological characteristics are missing.^{2,9} We have observed a subepidermal sclerosis in only up to 38% of the LS patients. It is important to underline that non-sclerotic cases may be frequent in the early stage of the disease.

Another important characteristic was a loss of the rete ridges of the epidermis found in up to 24% of the LS cases and in none of the non-LS cases. It may be a useful criterion, to differentiate LS from LP, where the rete ridges are usually saw-tooth-like and elongated.

In the LS group, a moderate/strong dermal inflammation was frequently (70%) observed, comparing to non-LS cases, which showed mostly (82%) a mild/absent inflammation. This well defines the second most common diagnosis of our non-LS group, namely LSC, a consequence of chronic itch, without inflammatory background dermatosis.

In one third of the LS cases, as previously reported,^{2,8} the elastic fibres were lost within the zones of sclerosis or fibrosis. This is not specific for LS and may be found also in other conditions, such as LP.⁹

We found apoptotic keratinocytes in the epidermis in up to 41% of the LS cases, mostly associated with a lichenoid inflammation (83% of those cases). Within 80% of the non-LS cases, single apoptotic keratinocytes were associated with a LSC/chronic eczema and not with lichenoid inflammation.

In conclusion, the diagnosis of female genital LS may be challenging, especially in its early stages, or when the typical histological features of LS are missing. We could define 10 histopathological criteria strongly associated with LS, which should be considered when distinguishing it from other vulvar dermatoses.

The study was funded by a grant of the Swiss National Science Foundation (SNF) (Grant 32003B_135568).

Acknowledgements

We thank hereby Univ. Prof. S. Regauer Pathologist, Austria, for histology interpretation suggestions and J. Wanner, study nurse.

K. Gadaldi,¹ S. Cazzaniga,^{1,2} L. Feldmeyer,¹ E. Krause,³ A.R. Günthert,⁴ H. Beltraminelli^{1,*}

¹Department of Dermatology, Inselspital Bern University Hospital, University of Bern, Bern, Switzerland, ²Centro Studi GISED, Bergamo, Italy, ³Department of Gynecology, Inselspital Bern University Hospital, University of Bern, Bern, Switzerland, ⁴gyn-zentrum ag, Lucerne, Switzerland

*Correspondence: H. Beltraminelli. E-mail: helmut.beltraminelli@insel.ch

References

- 1 Fistarol SK Itin PH. Diagnosis and treatment of lichen sclerosis: an update. *Am J Clin Dermatol* 2013; **14**:27-47.
- 2 Carlson JA, Lamb P, Malfetano J, Ambros RA Mihm MC. Clinicopathologic comparison of vulvar and extragenital lichen sclerosis: histologic

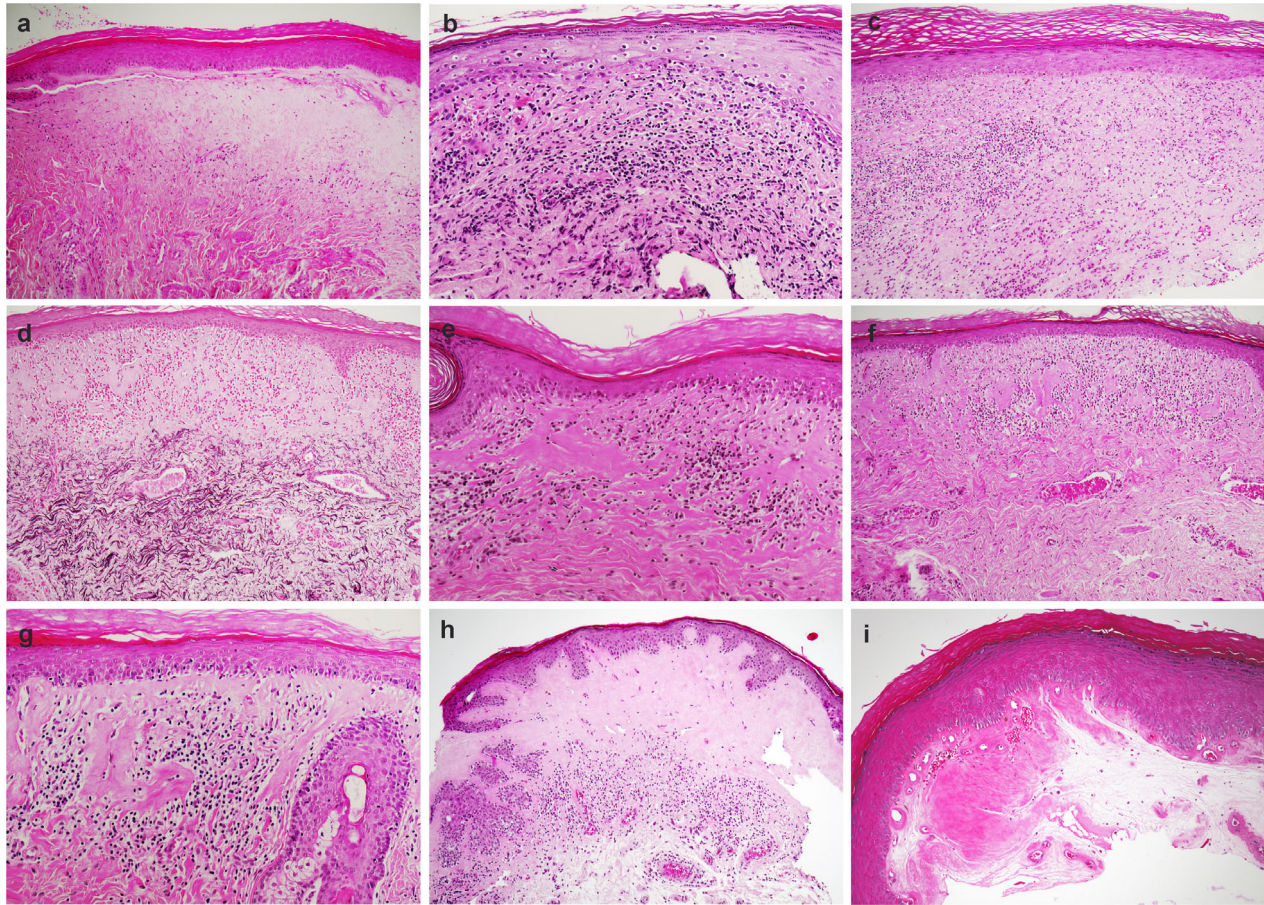


Figure 1 Nine pictures showing the 10 significant histopathological features. (a) subepidermal sclerosis, (b) moderate–strong dermal inflammation, (c) apoptotic keratinocytes, band-like inflammation, moderate–strong dermal inflammation and dermal fibrosis, (d) loss of elastic fibres within sclerosis, (e) lichenoid inflammation, apoptotic keratinocytes and absence of epidermal acanthosis, (f) subepidermal sclerosis, absence of epidermal acanthosis and band-like inflammation and loss of rete ridges, (g) subepidermal sclerosis, apoptotic keratinocytes, absence of epidermal acanthosis, lichenoid inflammation, (h) subepidermal sclerosis, absence of epidermal acanthosis and band-like inflammation, and (i) erythrocytes extravasation.

- variants, evolving lesions, and etiology of 141 cases. *Mod Pathol* 1998;11:844–854.
- 3 Günthert AR, Duclos K, Jahns BG *et al*. Clinical scoring system for vulvar lichen sclerosis. *J Sex Med* 2012; 9:2342–2350.
 - 4 Regauer S, Liegl B Reich O. Early vulvar lichen sclerosis: a histopathological challenge. *Histopathology* 2005; 47:340–347.
 - 5 Chan MP Zimarowski MJ. Vulvar dermatoses: a histopathologic review and classification of 183 cases. *J Cutan Pathol* 2015; 42:510–518.
 - 6 Carlson JA, Ambros R, Malfetano J *et al*. Vulvar lichen sclerosis and squamous cell carcinoma: a cohort, case control, and investigational study with historical perspective; implications for chronic inflammation and sclerosis in the development of neoplasia. *Hum Pathol* 1998; 29:932–948.
 - 7 Fung MA LeBoit PE. Light microscopic criteria for the diagnosis of early vulvar lichen sclerosis: a comparison with lichen planus. *Am J Surg Pathol* 1998; 22:473–478.
 - 8 Knio Z, Kurban M Abbas O. Lichen sclerosis: clinicopathological study of 60 cases from Lebanon. *Int J Dermatol* 2016; 55:1076–1081.
 - 9 Niamh L, Naveen S Hazel B. Diagnosis of vulval inflammatory dermatoses: a pathological study with clinical correlation. *Int J Gynecol Pathol* 2009; 28:554–558.
- DOI: 10.1111/jdv.16368